

Geometric Characterization of Cricoid Cartilage in Indian Population for Biomechanical Modeling

Yadav Y¹, Tuli A², Kakar S², Choudhry R², Murari A³

¹Department of Anatomy, Rama Medical college, Hapur, UP

²Department of Anatomy, Lady Hardinge Medical College and Smt. Sucheta Kriplani Hospitals.

³Department of Forensic, Lady Hardinge Medical College and Smt. Sucheta Kriplani Hospitals

Abstract: The complex anatomy of the vertebrate larynx shows a steady progression from the simple slit on the floor of the lungfish's pharynx to the fine-tuned mechanism of the human vocal apparatus. The study was conducted on 50 cricoid cartilages (36 males & 14 females) obtained from unclaimed bodies in the Deptt. of Forensic medicine, LHMC. This study attempts to define and measure some biomechanically important morphometric features of cricoid cartilage which are useful for constructing quantitative biomechanical models of vocal fold vibration and posturing. The dimensions and geometric positions of Cricothyroid (CT) and Cricoarytenoid (CA) facets with respect to the laryngeal framework are biomechanically important, as they contribute to the determination of CT and CA translation rotational dynamics, which are critical for length changes and posturing (abduction and adduction) of vocal cords.

Keywords: laryngeal framework, cricoid cartilage, morphometric measurements.

1. Introduction

The precise understanding of anatomical structures is the basic precondition of any surgical intervention. There are several reasons why the dimensions of the larynx should be known, such as for intubation, endoscopic procedures, stenting, cricothyroidotomy and transplantation. In the region of head and neck, the increasing application of sophisticated electrophysiological and surgical methods in diagnosis and treatment of laryngeal disorders i.e. subglottic stenosis and post intubation stenosis of lower respiratory tract, require a profound knowledge of size and proportion of human larynx and its cartilaginous components, especially cricoid cartilage. Immediately below the thyroid cartilage and articulating with it, is cricoid cartilage, which is shaped like a signet ring. It is the only complete cartilaginous ring of larynx. The cartilage possesses a posterior quadrangle lamina and a narrow anterior arch. The lamina has a median vertical ridge on its posterior surface to which two fasciculi of the longitudinal muscle fibers of the esophagus attached. On each side of this ridge, a shallow depression gives rise to the fibers of origin of posterior cricoarytenoid muscle. The cricoid cartilage has two articular facets on each sides for articulation with other laryngeal cartilages i.e. (i) one facet is on the sloping superolateral surface of the lamina and articulates with the base of an arytenoid cartilage; (ii) the other facet is on the lateral surface of the lamina near its base and is for articulation with the medial surface of the inferior horn of the thyroid cartilage. The cricoid is composed of hyaline cartilage, which undergoes variable ossification with advancing age which is especially pronounced in lamina [1, 2&3].

2. Material & Methods

The study was conducted in Department of Anatomy, Lady Hardinge Medical College (LHMC) & associated S.K. Hospital on 50 cricoid cartilages (36 males & 14 females). The specimens were obtained during autopsy of unclaimed bodies from Department of Forensic Medicine, LHMC & associated S.K. Hospital. The larynges were removed together with trachea from level of hyoid bone to third tracheal ring only when autopsy records, premorbid medical records and gross examination revealed no anatomical abnormalities. During autopsy, a midline incision was given from chin to pubic symphysis to examine various viscera. After identifying the thyroid prominence, larynx was removed en bloc from base of tongue to the second or third tracheal ring. After removal, it was washed under running water and soft tissues removed. After careful removal of all muscles and ligamentous attachments the cartilages were measured in all their dimensions with help of scale, Vernier caliper and a goniometer. Geometric measurements on the laryngeal framework necessary for modeling purposes were defined as follows:

- (i) Anterior arch, height: the height of the anterior arch in median plane (K-K').
- (ii) Anterior arch, antero-posterior thickness: the thickness of the anterior arch in median plane (K'-P').
- (iii) Posterior wall, height: the height of the lamina in the median plane (L-L').
- (iv) Posterior wall, left to right width: the distance between the centers of the cricothyroid articular facets (10-10').
- (v) Inside diameter, antero-posterior (cranial edge): inner distance between anterior arch and the posterior lamina at cranial edge in median plane (I'-K').

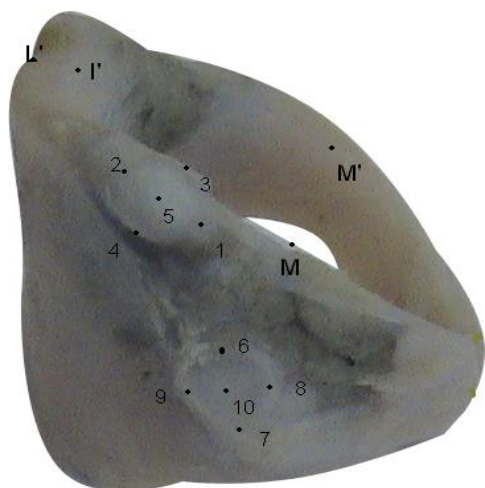
- (vi) Inside diameter, antero-posterior (caudal edge): inner distance between anterior arch and the posterior lamina at caudal edge in median plane (I-K).
- (vii) Inside diameter, left to right (cranial edge): inner distance between the cricoid arch at cranial edge at the level of the cricothyroid articular facets (M-M').
- (viii) Inside diameter, left to right (caudal edge): inner distance between the cricoid arch at caudal edge at the level of the cricothyroid articular facets (N-N').
- (ix) Cricothyroid articular facet, major diameter: the length of cricothyroid articular facet in antero-posterior direction (8-9).
- (x) Cricothyroid articular facet, minor diameter: the width at the centre of cricothyroid articular facet perpendicular to major diameter (6-7).
- (xi) Cricoarytenoid articular facet, major diameter: length of the cricoarytenoid articular facet in downward forward and lateral direction (1-2).
- (xii) Cricoarytenoid articular facet, minor diameter: width at the centre of the cricoarytenoid articular facet perpendicular to major diameter (3-4).
- (xiii) Position of cricothyroid facet in polar coordinate: the position of cricothyroid articular facet in polar co-ordinates (Point L is the origin; rCT is the distance between point L to the centre of the cricothyroid facet (10) and θ CT is the angle between rCT and horizontal line along point L.)
- (xiv) Position of cricoarytenoid facet in polar coordinate: the position of cricoarytenoid articular facet in polar co-ordinates (Point L is origin; rCA is the distance between

point L to the centre of the cricoarytenoid facet (5) and θ CA is the angle between rCA and horizontal line along point L.) Point L was defined as the most inferior and posterior point of the cricoid cartilage in the midsagittal plane.

All linear measurements were made with a Vernier caliper corrected to the nearest 0.01 mm. Angle measurements were made with Goniometer in degrees corrected to the nearest whole degree. All the measurements were taken three times and mean of three taken into account.

3. Observations

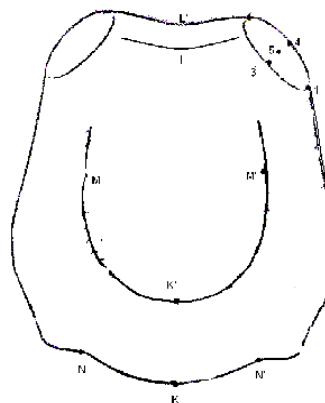
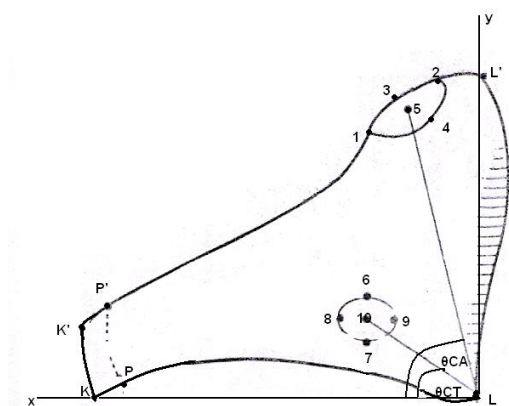
The data obtained from measurement of 50 cricoid cartilages (36 males & 14 females) were analyzed by Student's T-test. p-value obtained by this test said to be significant if it is less than 0.05, highly significant if p value <0.01 and very highly significant if p value <0.001. The average age of males was 42.6 ± 8.7 years, maximum being 58 years and minimum 28 years. The average age of females was 30.2 ± 6.6 years; maximum was 39 years and minimum 22 years {p = 0.001}. The average height of males was 163.1 ± 3.6 cm (max. 171 cm & min. 157 cm; in females that was 156.0 ± 3.4 cm (max. 161 cm & min. 151 cm) {p = 0.000}. The cricothyroid (CT) facets were variable in size, shape, and configuration. Some of them exhibited soft tissue facet only, and after removal of this tissue revealed either a flat cartilage surface or a slight protuberance with no definable facet. (Table-I)



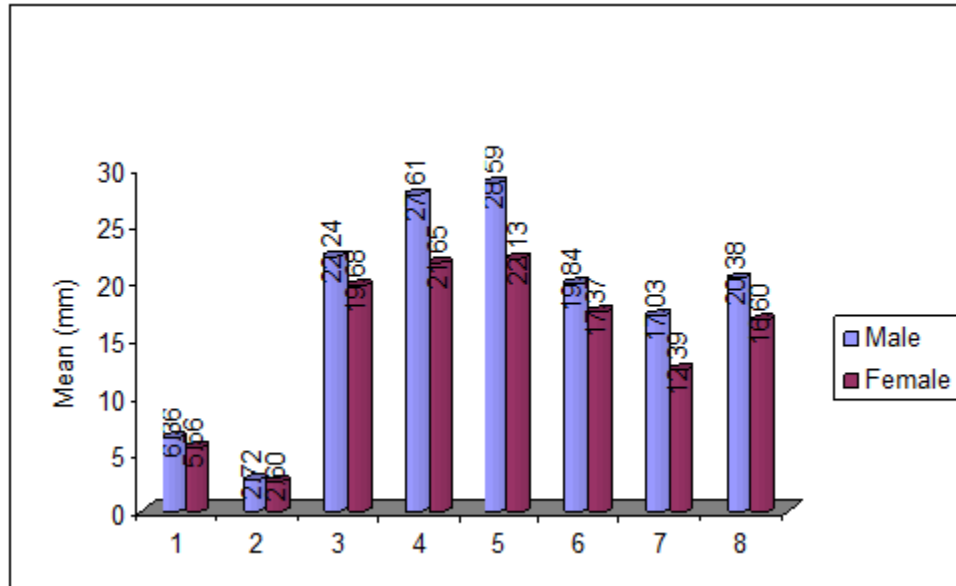
Cricoid (Lateral view)



Cricoid (Superior view)

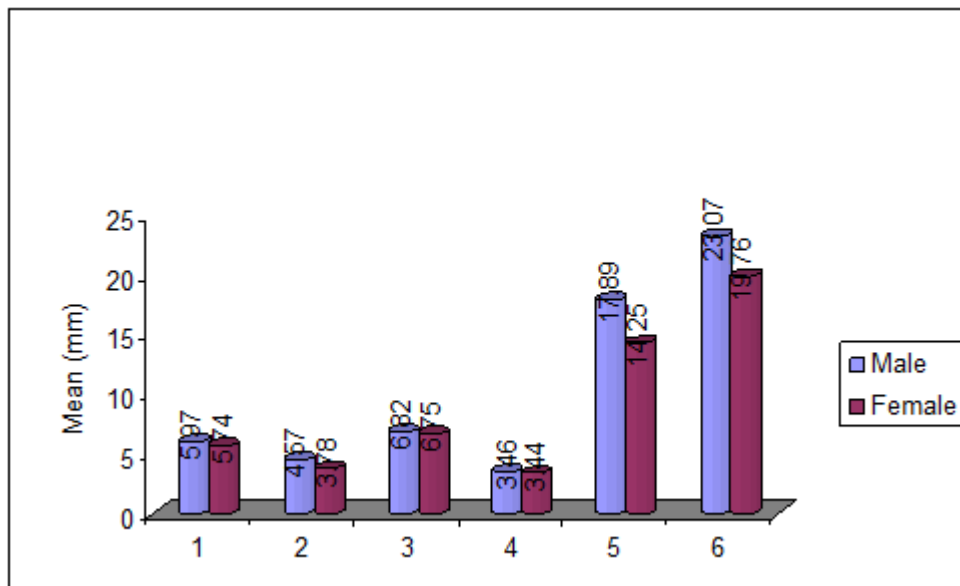


Cricoid (Superior view)



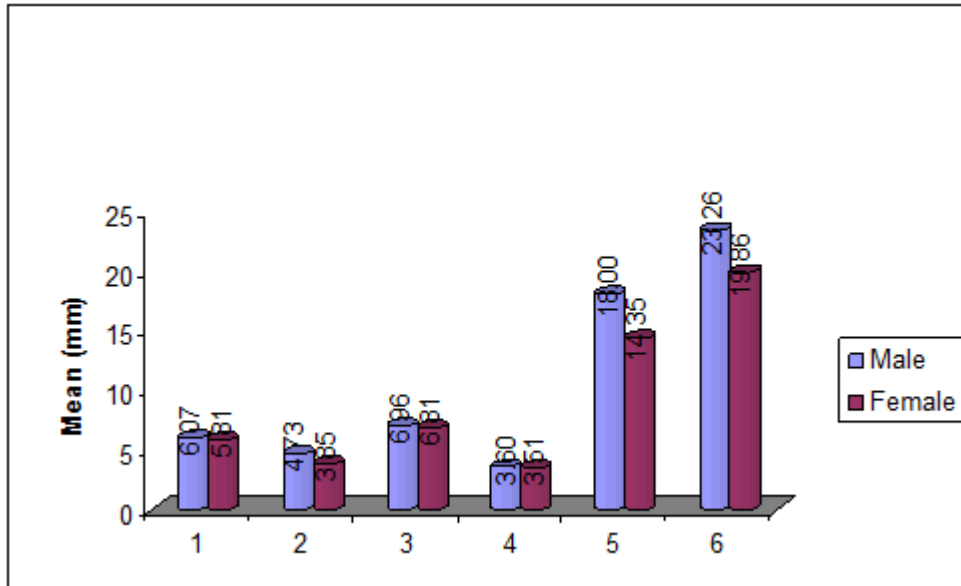
Graph-1: Showing various dimensions of cricoid cartilage in males & females

1. Anterior arch, superior- inferior height
2. Anterior arch, anterior-posterior thickness
3. Posterior wall, superior- inferior height
4. Posterior wall, left to right width
5. Inside diameter, anterior-posterior (cranial edge)
6. Inside diameter, anterior-posterior (caudal edge)
7. Inside diameter, left to right (cranial edge)
8. Inside diameter, left to right (caudal edge)



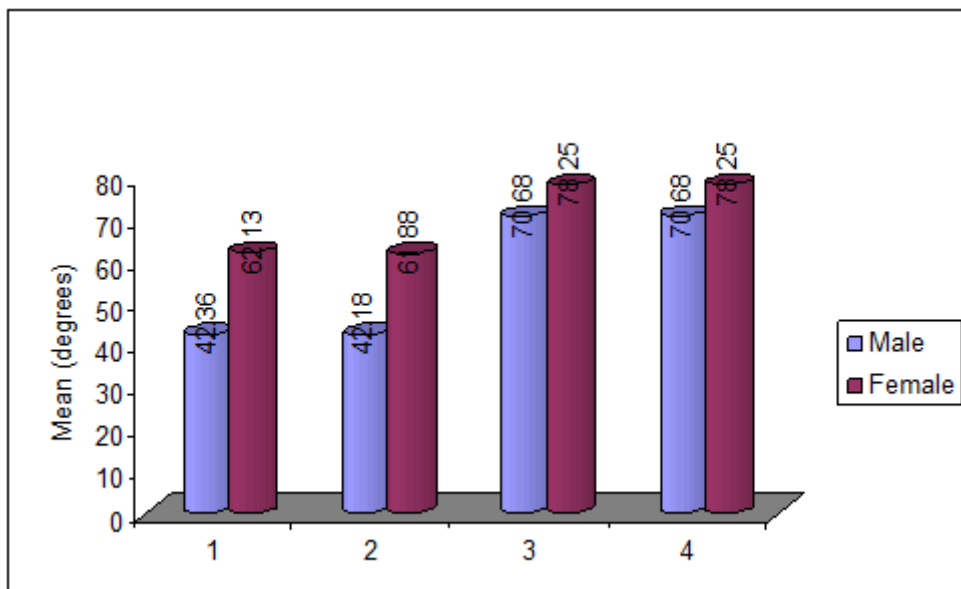
Graph2: Comparing diameter and distances of right articular facets of cricoid cartilages in males & females

1. Cricothyroid articular facet, major diameter (rt)
2. Cricothyroid articular facet, minor diameter (rt)
3. Cricoaarytenoid articular facet, major diameter (rt)
4. Cricoaarytenoid articular facet, major diameter (rt)
5. Position of cricothyroid facet in polar coordinate (rt)-distance
6. Position of cricoarytenoid facet in polar coordinate (rt)-distance



Graph3: Comparing diameter and distances of left articular facets of cricoid cartilages in males & females

1. Cricothyroid articular facet, major diameter (lt)
2. Cricothyroid articular facet, minor diameter (lt)
3. Cricoarytenoid articular facet, major diameter (lt)
4. Cricoarytenoid articular facet, minor diameter (lt)
5. Position of cricothyroid facet in polar coordinate (lt)-distance
6. Position of cricoarytenoid facet in polar coordinate (lt)-distance



Graph 4: Comparing various angles of cricoid cartilage in males & females

1. Position of cricothyroid facet in polar coordinate (rt)-angle
2. Position of cricothyroid facet in polar coordinate (lt)-angle
3. Position of cricoarytenoid facet in polar coordinate (rt)-angle
4. Position of cricoarytenoid facet in polar coordinate (lt)-angle

S. No.		Male		Female		P-Value
		MEAN	SD+/-	MEAN	SD+/-	
1	Anterior arch, superior- inferior height	6.36	0.76	5.56	0.39	0.001
2	Anterior arch, anterior-posterior thickness	2.72	0.40	2.60	0.33	0.419
3	Posterior wall, superior- inferior height	22.24	1.27	19.68	0.59	0.000
4	Posterior wall, left to right width	27.61	1.29	21.65	1.50	0.000
5	Inside diameter, anterior-posterior (cranial edge)	28.59	1.30	22.13	1.42	0.000
6	Inside diameter, anterior-posterior (caudal edge)	19.84	1.40	17.37	0.21	0.000
7	Inside diameter, left to right (cranial edge)	17.03	1.40	12.39	0.50	0.000
8	Inside diameter, left to right (caudal edge)	20.38	1.76	16.60	0.30	0.000
9	Cricothyroid articular facet, major diameter (rt)	6.07	0.24	5.81	0.27	0.036
10	Cricothyroid articular facet, major diameter (lt)	5.97	0.23	5.74	0.27	0.062
11	Cricothyroid articular facet, minor diameter (rt)	4.73	0.49	3.85	0.29	0.000
12	Cricothyroid articular facet, minor diameter (lt)	4.57	0.45	3.78	0.27	0.000
13	Cricoaarytenoid articular facet, major diameter (rt)	6.96	0.64	6.81	0.29	0.401
14	Cricoaarytenoid articular facet, major diameter (lt)	6.82	0.61	6.75	0.31	0.682
15	Cricoaarytenoid articular facet, minor diameter (rt)	3.60	0.35	3.51	0.23	0.452
16	Cricoaarytenoid articular facet, minor diameter (lt)	3.46	0.25	3.44	0.19	0.812
17	Position of cricothyroid facet in polar coordinate (rt)-distance	18.00	0.29	14.35	0.54	0.000
18	Position of cricothyroid facet in polar coordinate (rt)-angle	42.36	2.38	62.13	3.52	0.000
19	Position of cricothyroid facet in polar coordinate (lt)-distance	17.89	0.31	14.25	0.53	0.000
20	Position of cricothyroid facet in polar coordinate (lt)-angle	42.18	2.42	61.88	3.72	0.000
21	Position of cricoarytenoid facet in polar coordinate (rt)-distance	23.26	1.26	19.86	0.47	0.000
22	Position of cricoarytenoid facet in polar coordinate (rt)-angle	70.68	1.43	78.25	1.67	0.000
23	Position of cricoarytenoid facet in polar coordinate (lt)-distance	23.07	1.32	19.76	0.45	0.000
24	Position of cricoarytenoid facet in polar coordinate (lt)-angle	70.68	1.73	78.25	1.83	0.000

Table- 1: Showing various parameters of Cricoid cartilage in male and female

	Present Study		Ajmani (Indian)[4]		Tayama [5]		Eckel [6]		Zrunek [7]		Ajmani (Nigerian)[8]		Maue [9]		Harjeet [10]		Randestad [11]	
	M	F	M	F	M	F	M	F	M	F	M	F	M	F	M	F	M	F
	CRICOID																	
Anterior arch, superior- inferior height	6.3 6	5.5 6			7. 05	5.4 0	6. 90	6.2 0	8. 10	6.8 0								
Anterior arch, anterior-posterior thickness	2.7 2	2.6 0			3. 16	2.5 8									6.1 3	4. 9	23.3 0	21. 00
Posterior wall, superior- inferior height	22. 24	19. 68	20.0 0	19.3 0	22. .6	19. 63	24. .6	21. 30	25. .3	19. 30	26.50	24.60						
Posterior wall, left to right width	27. 61	21. 65			29. .8	21. 76									21. 82	1. 8		
Inside diameter, anterior-posterior (cranial edge)	28. 59	22. 13			29. .3	23. 66	21. .6	17. 40										
Inside diameter, anterior-posterior (caudal edge)	19. 84	17. 37	22.0 0	18.3 0	20. .4	17. 47	20. .1	16. 40	20. .7	16. 00	28.82	24.06	3. 10	3.1 4			24.0 0	18. 50
Inside diameter, left to right (cranial edge)	17. 03	12. 39	22.3 0	18.9 0	18. .2	12. 79	15. .3	12. 00	21. .4	15. 90	29.84	25.84			20. 22	1. 5		
Inside diameter, left to right (caudal edge)	20. 38	16. 60			22. .3	16. 82	18. .2	14. 50					24. .5	19. 13	16. 53	1. 2	17.6 0	13. 70
Cricothyroid articular facet, major diameter (rt)	6.0 7	5.8 1			6. 15	5.9 6												
Cricothyroid articular facet, major diameter (lt)	5.9 7	5.7 4																
Cricothyroid articular facet, minor diameter (rt)	4.7 3	3.8 5			4. 73	3.7 3							16. .0	16. 43				
Cricothyroid articular facet, minor diameter (lt)	4.5 7	3.7 8																
Cricoaarytenoid articular facet, major diameter (rt)	6.9 6	6.8 1			8. 04	6.8 5	8. 80	7.2 0										
Cricoaarytenoid articular facet, major diameter (lt)	6.8 2	6.7 5					8. 60	7.2 0							7.5 4	6. 1	9.20 9	7.4 0

Cricoarytenoid articular facet, minor diameter (rt)	3.6 0	3.5 1	4. 07	3.4 8	5. 20	4.4 0	7.6 0	6. 2 0		
Cricoarytenoid articular facet, minor diameter (lt)	3.4 6	3.4 4			4. 70	4.7 0	3.6 9	3. 1 9	4.70	4.4 0
Position of cricothyroid facet in polar coordinate (rt)-distance	18. 00	14. 35	17. .3	14. 20			3.7 1	3. 2 0		
Position of cricothyroid facet in polar coordinate (rt)-angle	42. 36	62. 13	45. .8	71. 33			7. 38	6.0 7		
Position of cricothyroid facet in polar coordinate (lt)-distance	17. 89	14. 25					7. 72	5.9 9		
Position of cricothyroid facet in polar coordinate (lt)-angle	42. 18	61. 88					4. 48	3.8 1		
Position of cricoarytenoid facet in polar coordinate (rt)-distance	23. 26	19. 86	23. .1	19. 84			4. 48	3.7 3		
Position of cricoarytenoid facet in polar coordinate (rt)-angle	70. 68	78. 25	71. .1	78. 33						

Table2: Comparison between Various Studies

4. Discussion

In Homo sapiens, vocal performance has reached its highest degree of versatility, with a vocal fold capable of adjustment in length, tension and shape. In the course of organic evolution, man appears to have chosen the ability to speak and sing over the security that an intranarial epiglottis would have given him. [12] In the region of head and neck, the increasing application of sophisticated electrophysiological and surgical methods in diagnosis and treatment of laryngeal disorders i.e. subglottic stenosis and post intubation stenosis of lower respiratory tract, require a profound knowledge of size and proportion of human larynx and its cartilaginous components. [6]

Observations on cricoid cartilages revealed similarity in the height, anteroposterior dimension and lateral dimension. Thus, the length, width and height measurements of cartilages show that cricoid cartilage is roughly cuboidal. The transverse diameter of cricoid was more in male than in female. The difference between male and female diameter was 4.2 mm on average in the present study. The transverse diameter of cricoid at the cranial edge was less than the caudal edge i.e. it is increasing cranial to caudally to accommodate the wider tracheal ring. The dimensions and geometric positions of CT and CA facets with respect to the laryngeal framework are biomechanically important. The anterior gap between the thyroid cartilage and the cricoid cartilage was 9.91 ± 0.35 mm in male and 8.70 ± 0.31 in female ($p = 0.000$). This distance is very important for biomechanical modeling vocal cord length changes and fundamental frequency control. Comparison of present observations in north Indian population with other populations [Table-II] reveals that the absolute values differ greatly in different populations which could be due to differences in body built and racial differences.

5. Conclusion

The dimensions and geometric positions of CT and CA facet with respect to the laryngeal framework are biomechanically important, as they contribute to the determination of CT and CA translation rotational dynamics, which are critical for length changes and posturing (abduction and adduction) of vocal cords. The morphometric data obtained are useful for construction and refinement of quantitative biomechanical models of vocal fold vibration and posturing, e.g. continuum

mechanical models [13] and finite-element models of vocal folds. [14] The morphometric data we obtained in Indian population differ greatly from different populations, so our data can be used for construction of vocal fold/laryngeal models for Indian population specifically. Asymmetry was found in the shape and size of the CA facet and CT facet. We can further evaluate the effect of this asymmetry on dynamics of cricothyroid (CT) and cricoarytenoid (CA) joints.

References

1. Barry KB Berkovitz. Larynx. In: Susan Standing et al editors. Gray's Anatomy 39th ed. Elsevier Churchill Livingstone; 2004. p. 633-646.
2. Romanes GJ. Editors. Cunningham's manual of practical anatomy 15th ed. Oxford Medical Publication: 2002; p.157-166
3. Sinnatamby CS. Larynx. In: Last's Anatomy 10th ed. Churchill Livingstone: 2001. p. 383-388
4. Ajmani ML, Jain SP, Saxena SK. A metrical study of laryngeal cartilages and their ossification. Anat Anz 1980; 148(1):42-8.
5. Tayama N, Chan RW, Kaga K, Titze IR. Geometric characterization of the laryngeal cartilage framework for the purpose of biomechanical modeling. Ann Otol Rhinol Laryngol 2001 Dec; 110(12):1154-61
6. Eckel HE, Sittel C, Zorowka P, Jerke A. Dimensions of the laryngeal framework in adults. Surg Radiol Anat 1994; 16(1):31-36
7. Zrunek M, Happak W, Hermann M, Streinzer W. Comparative anatomy of human and sheep laryngeal skeleton. Acta Otolaryngol 1988; 105:155-162
8. Ajmani ML. A metrical study of the laryngeal skeleton in adult Nigerians. J Anat 1990 Aug; 171:187-191
9. Maue WM, Dickson DR. Cartilages and ligaments of the adult human larynx. Arch otolaryngol 1971; 94:432-439
10. Harjeet, Jit I, Sahni D. Dimensions & weight of the cricoid cartilage in northwest Indians. Indian J Med Res 2002 Nov; 116:207-16

11. Randestad A, Lindholm CE, Fabian P. Dimensions of the cricoid cartilage and the trachea. *Laryngoscope*. 2000 Nov; 110(11):1957-61.
12. Kirchner JA. The vertebrate larynx: adaptations and aberrations. *Laryngoscope*. 1993 Oct; 103(10):1197-201.
13. Berry DA, Titze IR. Normal modes in a continuum model of vocal fold tissues. *J Acoust Soc Am* 1996;100:3345-54
14. Alipour F, Berry DA, Titze IR. A finite-element model of vocal-fold vibration. *J Acoust Soc Am* 2000;108:3003-12

Author's profile:



Dr Yogesh Yadav* received MBBS,MD (Anatomy) from MAMC & LHMC respectively.Now working as Associate Professor in Rama Medical College,Hospital and Research Center,Hapur,UP