

# Persistent Foramen Tympanicum: Incidence and Clinical Implication

Yogesh Yadav<sup>1</sup>, Preeti Goswami<sup>2</sup>, Mohit Makkar<sup>3</sup>

<sup>1,2</sup>Dept. of Anatomy Rama Medical College, Hapur, UP

<sup>3</sup>Dept. of Pharmacology, Win Medicare, Delhi

*dryogeshyadav@gmail.com*

*drpreetigoswami@gmail.com*

*mohitmakkar\_mm@gmail.com*

---

**Abstract:** The deficiency in the antero-inferior wall of the bony part of external auditory canal (EAC) closes by 5 years of age but if it persists beyond that age it is called foramen Tympanicum. Depending on the population studied, persistence of this foramen has been seen in 0-67% of adult crania. Review of literature revealed that no data was available in North Indian population; therefore the present study is being undertaken. 30 adult human crania were examined and the presence of foramen Tympanicum was noted. The side to which it belonged to, its shape and size were observed. Out of 30 adult human crania seen, foramen Tympanicum was present in 9 crania. It was observed unilaterally in 4 crania and bilaterally in 5. Although different shapes of the foramen like pin point, pin head, irregular and U shape were observed but in majority of cases it was irregular shaped. This study revealed that about 30% of North Indian adult human crania have foramen Tympanicum. Persistent foramen Tympanicum in the adult life may be involved in different abnormalities of the EAC and may lead to otological complications. Therefore, ENT surgeons should be aware of persistent foramen Tympanicum and keep it as one of the possible diagnoses while dealing with patients presenting with otological complications. Also the surgeons should be careful while performing endoscopy of Temporomandibular Joint (TMJ) so that accidental damage of TMJ can be prevented.

**Keywords:** Crania, Endoscopy, Foramen Tympanicum, Otological complications, External auditory canal, temporomandibular joint

---

## 1. Introduction

If a deficiency in the antero-inferior wall of EAC, formed by tympanic part of the temporal bone, in human crania persists after 5 years of age then it is called Foramen Tympanicum [1]. Foramen Tympanicum can either be asymptomatic or it may cause a persistent ear discharge after mastication in which case it might be connected to the TMJ or to the parotid gland [2-4]. It may also lead to inadvertent passage of the endoscope into the TMJ leading to its damage [5- 7]. Literature search did not reveal any data on the presence of this foramen in the adult North Indian population. Therefore, 30 North Indian adult human skulls were examined for the presence of foramen Tympanicum. The shape, size and the side to which it belonged to were noted and analyzed

## 2. Methods

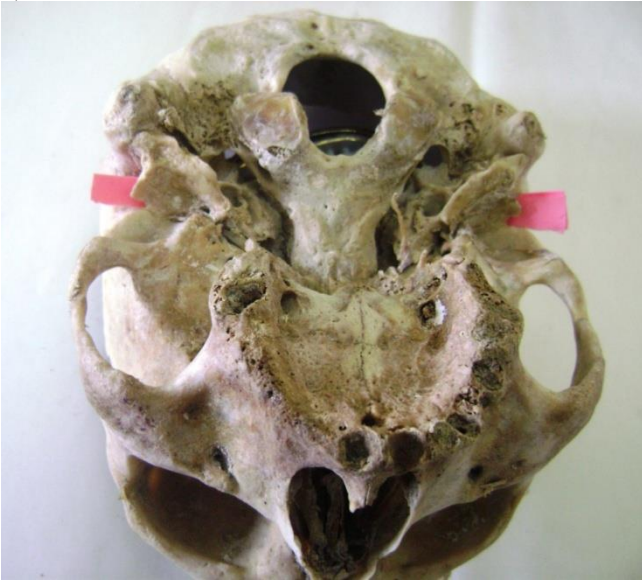Dry adult human crania were studied from Anatomy Department of Rama Medical College. Only those crania were selected in which tympanic plates were intact. So a

total of thirty dry adult North Indian human crania were finally available for the study. Any deficiency in the tympanic plate called foramen Tympanicum was observed meticulously. The side and shape of foramen Tympanicum was recorded and analyzed.

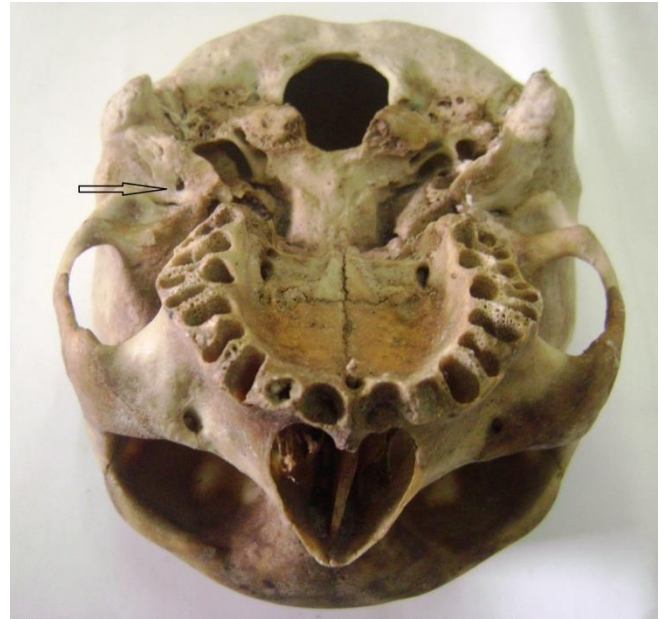
## 3. Results

Foramen Tympanicum was observed in 9 dry human adult crania out of a total of 30 crania examined. It was present unilaterally in 4 crania (right=2, left=2) and was bilateral in 5 (Table 1) (Figure 1, 2, 3& 4). Pin point, irregular, and U shaped foramen Tympanicum were observed (Figure. 1, 2, 3& 4) but most commonly irregular foramina were seen (Table 2, Figure

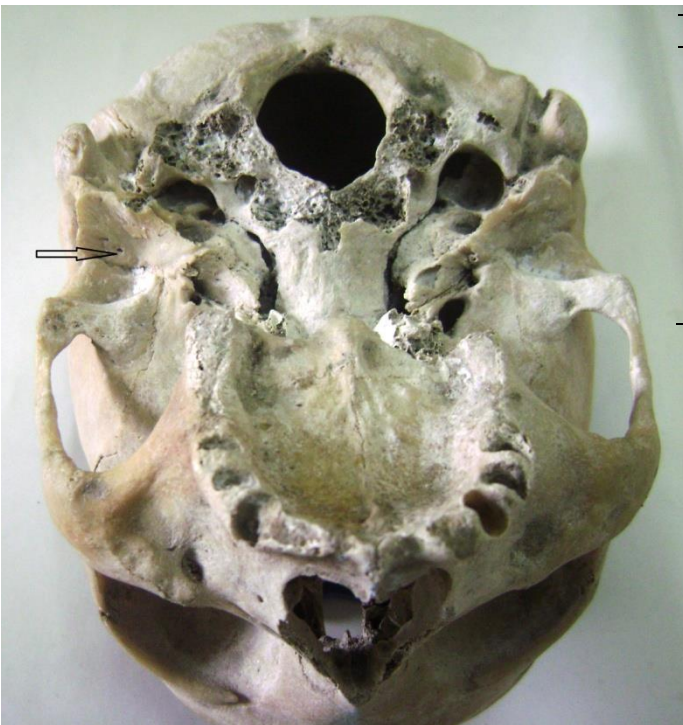3).



**Figure-1:** Bilateral U shaped foramen tympanicum



**Figure-3:** Left side irregular shaped foramen tympanicum



**Figure-2:** Left side pin point shaped foramen tympanicum

Sr. No.	Right side	Left side
1	+	+
2	+	+
3	+	+
4	+	+
5	+	+
6	+	-
7	+	-
8	-	+
9	-	+

**Table 1:** Side of foramen Tympanicum in the crania showing this foramen.



**Figure-4:** Right side irregular shaped foramen tympanicum

Sr. No.	Right side	Left side
1	U	U
2	U	U
3	U	U
4	I	I
5	I	I
6	I	-
7	I	-
8	-	P
9	-	I

Table 2: Different shapes of foramen Tympanicum

U-U shaped, P- pinpoint, I- Irregular

#### 4. Discussion

The foramen Tympanicum is a bony defect in the anteroinferior wall of external acoustic canal after 5 years of age. Anteroinferior wall of EAC is formed by tympanic bone, which develops from a membranous ossification process [7, 8]. It was first described by a German anatomist and embryologist professor Emil Huschke (1797 - 1858) [9]. Therefore, foramen Tympanicum is also known as foramen of Huschke. It connects the EAC to the temporomandibular joint. At birth, the tympanic bone is developed incompletely and forms a U shape. Two prominences, one anterior and one posterior to the U-shaped bone develop and grow toward each other and fuse from lateral to medial side by 5 year of age. Therefore, if the point of fusion does not properly extend medially then the foramen persisting medial to the point of fusion is called foramen of Huschke. In most children, this foramen becomes smaller gradually and closes completely by 5 years of age. It may persist occasionally [8]. Hence, deficiency in the antero-inferior wall of EAC formed by tympanic part of the temporal bone should be considered as anatomic variant only after 5 years of age [10]. Wang et al. (1991) conducted an osteologic study on 377 skulls and found persistence of foramen of Huschke to be 7.2%. They found a difference in rate of persistence of this foramen in different population. In the skulls of Chinese origin it was 6.7%. Persistence of the foramen was seen in 9.1% of the skulls from Toronto [11]. Persistence of foramen of Huschke was found to be 30% in the present study (Table 1). Higher rate of persistence of foramen of Huschke in crania of Indian origin in comparison to the study of Wang et al could be an ethnic variation. Toyama et al. (2009) noted unilateral presentation of foramen of Huschke in most of the patients as was observed in the current study in which this foramen was unilateral in 5 crania (right = 2, Left = 4) and bilateral in 3 crania only [12]. Srimani et al. (2013) studied 53 crania and observed foramen of Huschke in 7 of them. Foramen of Huschke was on the left side in all the seven crania though was unilateral in three only [13]. Our study was in contrast to Srimani et al. as this foramen was seen unilaterally in 2 crania on the right side also (Figure 1). The shapes of foramen of Huschke observed

in this study were pin point, irregular and U shaped (Figure 1, 2, 3& 4). Srimani et al. noted pin head, circular, oval and triangular foramen in their study [13]. Ethnic variation may be the reason.

Knowledge of this anatomical defect may be useful in evaluating patients with short lived otorrhoea where no local cause is identified. Persistent ear discharge after mastication may be due to the connection of this foramen with the TMJ or with the parotid gland. Awareness of presence of foramen of Huschke may prevent inadvertent passage of the endoscope into the TMJ and ultimately resulting in its damage. If this foramen is present, infection may spread from EAC to infra-temporal fossa and vice versa. Data obtained from our study may not only benefit anatomists but also ENT surgeons, dentists and radiologists.

#### References

- Warwick R, Williams PL, Dyson M, Bannister LH. External and middle ear. In: Standring S, eds. Gray's Anatomy. The Anatomical Basis of Clinical Practice. 40th ed. London: Churchill Livingstone; 2008: 615-617.
- Lacout A, Marsot-Dupuch K, Smoker WRK, Lasjaunias P. Foramen tympanicum, or foramen of Huschke: pathologic cases and anatomic CT study. *Am J Neuroradiol.* 2005; 26(6):1317-23
- Sharma PD, Dawkins RS. Patent foramen of Huschke and spontaneous salivary fistula. *J Laryngol Otol.* 1984; 98(1):83-85
- Chilla R. Otosialorrhoea: a rare case of a spontaneous salivary fistula of the external auditory canal. *HNO.* 2002; 50(10):943-5
- Applebaum EL, Berg LF, Kumar A, Mafee MF. Otolgic complications following temporomandibular joint arthroscopy. *Ann Otol Rhinol Laryngol.* 1989; 97(6 Pt 1):675-9
- Herzog S, Fiese R. Persistent foramen of Huschke: possible risk factor for otologic complications after arthroscopy of the temporomandibular joint. *Oral Surg Oral Med Oral Pathol.* 1989; 68(3):267-70
- Ars B. Le foramen de Huschke. *Acta Otorhinolaryngol Belg.* 1988; 42:654-58
- Stedman TL. Bone. In: Stedman TL, eds. Stedman's Medical Dictionary. 26th ed. Baltimore: Lippincott William & Wilkins; 1995: 674.
- Schacht J, Hawkins JE. Sketches of otohistory. Part 4: a cell by any other name: cochlear eponyms. *Audiol Neurootol.* 2004; 9:317-2
- Sperber GH. The temporomandibular joint. In: Derrich DD, eds. Craniofacial Embryology. 2nd ed. Chicago: John Wright & Sons; 1975:121-149.
- Wang RG, Bingham B, Hawke M, Kwok P, Li JR. Persistence of the foramen of Huschke in the adult: an osteological study. *J Otolaryngol.* 1991; 20:251-4.
- Toyama C, da Silva CJ, Fugita DY, Scapini F. Temporomandibular joint herniation into the external auditory canal. *Otol Neurotol.* 2009; 30:426-7.
- Srimani P, Mukherjee P, Ghosh E, Roy H. Variant presentations of "Foramen of Huschke" in seven adult human crania. *Int J Anat Var.* 2013; 6:120-3.

**Author's profile:**



**Dr Yogesh Yadav\*** received MBBS,MD(Anatomy) from MAMC & LHMC respectively.Now working as Associate Professor in Rama Medical College,Hospital and Research Center,Hapur,UP.

**Dr Preeti Goswami**-received MBBS, MD (Anatomy) degree from University College of Medical Sciences, Delhi. Now working as Assistant Professor in Rama Medical College, Hospital & Research Center, NH-24 Hapur,UP.